


NEANU

North of England
Acute Neurology
Update



5 Things About.....Thunderclap Headache

Dr Keira Markey

NIHR Academic Clinical Lecturer

MNeurosci MBChB MRCP PhD

Disclosures

- None





Objectives

- Definition of thunderclap headache (TH)
- History and examination.
- Differential diagnoses of TH.
- How to investigate and manage TH.
- Evidence-based approaches to TH.



Introduction

- Commonest headache condition is migraine.
- Commonest cause of TH is SAH..... but there are other causes.
- 50% of SAH does NOT present as a TH.
 - All will be a severe headache within an hour.



1. What is a Thunderclap Headache?

- TH is **severe /worst ever headache** and reaches peak severity **within a minute**.
- Patients remember what they were doing when it came on.
- Waking headaches are not TH.
- Lasts at least 1 minute up to 72 hrs.



2. The History is Key...



Severity

- Mild (1-3),
- Moderate (4-6),
- Severe (7-9),
- Worst-ever (10)

Timing

- Frequency
- Length of time
- How long to the maximum pain?

Triggers

- Exertion
- Emotional stress
- Sexual activity
- Postural changes
- Valsalva/Cough
- Showering/Bathing

Pregnancy/Post-partum

- History of pre-eclampsia
- 4-6 weeks PP period

Associated Features

- Visual symptoms
- N&V
- Photo/phonophobia
- Neck pain/stiffness
- LOC / seizures
- Focal deficits

Drug use

- Opiates
- Amphetamines,
- Cocaine
- SSRI

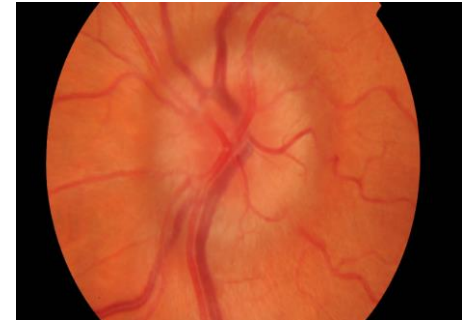


3. When is a thunderclap headache not SAH?



- Don't know until it is ruled out!
- 1/3 SAH misdiagnosed if presenting with normal level of consciousness and just headache.

- Recurrent
- Triggers
- Horner's
- U/L Mydriasis
+/- 3rd nerve palsy
- Papilloedema







Examination



Focal Neurology



Seizure activity




Pyrexia



Neck stiffness on passive movement



Blood pressure



Fundoscopy



Differentials of a TH

| Vascular | Benign | Other |
|--|---|--|
| SAH (Aneurysmal and non-aneurysmal) | New Daily Persistent Headache (NDPH) | Spontaneous Intracranial Hypotension (SIH) |
| Reversible Cerebral Vasoconstrictive Syndrome (RCVS) | Migraine | Meningo-encephalitis |
| Cerebral Venous Sinus Thrombosis (CVST) | Primary Sudden Onset Headache : Cough, Exertional, Sexual | Sinusitis |
| Dissection: Carotid or vertebral artery | Trigeminal Autonomic Cephalgia (TAC) e.g. Cluster. | Open Angle Glaucoma |
| Giant Cell Temporal Arteritis (GCTA) | | |
| Posterior Reversible Encephalopathy Syndrome (PRES) | | |
| Pituitary Apoplexy | | |

4. All thunderclap headaches
presenting for the first time need
extensive investigation



Case 1

- 57 yr old with sudden onset occipital headache associated with nausea, neck pain and some vomiting. Known HTN and previous MI on clopidogrel. No focal deficits.
- Presented at 24hrs and CT head performed, which was normal.
- How would you like to investigate?



How would you investigate?

① Start presenting to display the poll results on this slide.

To LP or not LP?

NICE guidance for suspected SAH (NG288)

1. If a CT head scan done within 6 hours of symptom onset and no SAH:
 - do not routinely offer a lumbar puncture
2. If a CT head scan done **more than 6 hours** after symptom onset shows no evidence of a subarachnoid haemorrhage, consider a lumbar puncture.
3. At least 12 hours after symptom onset before doing a lumbar puncture to diagnose a SAH.
4. Diagnose a SAH if the LP sample shows evidence of elevated bilirubin (xanthochromia) on spectrophotometry.
5. Think about alternative diagnoses if the LP sample shows no evidence of elevated bilirubin (xanthochromia) on spectrophotometry.

* 250 LPs are required to diagnose 1 additional SAH



Evidence

- Multicentre, international, retrospective observational study
- 14% (N=644) headaches to ED = TH.
- 50% from Australia and 10% from UK.
- **10.9% of TH has serious pathology.**
- 7.8% were found to have SAH by CT head.
- **Only 1 additional picked up by LP.**
- 75% LPs were normal. 11.8% inconclusive **and 10.3% showed infection (viral mostly).**
- 65.5% of TH were benign. **35% had no investigations!**

Roberts, Emerg Med J 2022; 39 803-809

| Characteristic | Likelihood ratio |
|---------------------------------|---------------------|
| +ve NC CT head within 6hrs | 230 (6-8700) |
| Visible xanthochromia | 24.67 (12.13-50.14) |
| Neck stiffness on examination | 6.59 (3.95-11.00) |
| CSF RBC >1000 x 10 ⁶ | 5.7 (1.4-23.0) |
| Neck pain history | 4.12 (2.24-7.59) |
| Headache onset >1hr | 0.06 (0-0.95) |
| -ve NC CT head within 6 hrs | 0.01 (0-0.04) |
| -ve NC CT head > 6hrs | 0.07 (0.01-0.61) |



Subarachnoid Haemorrhage (SAH)

- 50% mortality rate
- Most non-traumatic are aneurysmal.
- Non-aneurysmal causes: Vasc malformations, IC dissection, CVST, tumour, RCVS, CAA, pituitary apoplexy, vasculitis.
- 30-50% can have a sentinel bleed weeks prior to major bleed, presenting ONLY as headache.
- 70% have no neurological deficit

Ottawa SAH Rules:


- Tested extensively JAMA 2013, AJEM 2014, BMJ 2016, CMAJ 2017.
- 100% sensitivity in all but low specificity (8-15%)

Ottawa SAH Rule

The Ottawa Subarachnoid Hemorrhage Rule is for alert patients > 15 years old with new severe non-traumatic headache reaching maximum intensity within 1 hour

Not for patients with new neurological deficits, previous aneurysms, SAH, brain tumours, or history of similar headaches (≥ 3 episodes over ≥ 6 months)

Patient's require investigation if **one or more** findings present:

| | | |
|------------------------------------|---|---|
| 1 |  | 4 |
| Symptoms of neck pain or stiffness | | Onset during exertion |
| 2 | | 5 |
| Age ≥ 40 years old | | Thunderclap headache (peak intensity immediately) |
| 3 | | 6 |
| Witnessed loss of consciousness | | Limited neck flexion on exam |

Infographic created by Dr. Shahabz Syed, FRCPC, Department of Emergency Medicine, University of Ottawa.

Perry JJ, Sivilotti ML, Sutherland J, Hohl CM, Emmond M, Calder LA, Vaillancourt C, Thiruganasambandamoorthy V, Lesiak H, Wells GA, Stiel JC. Validation of the Ottawa Subarachnoid Hemorrhage Rule in Patients with Acute Headache. CMAJ. 2017;189(45):1379-1385.



5. Management is dependent
on the diagnosis

Case 2

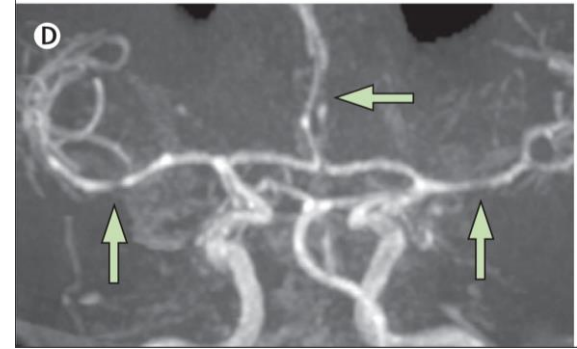
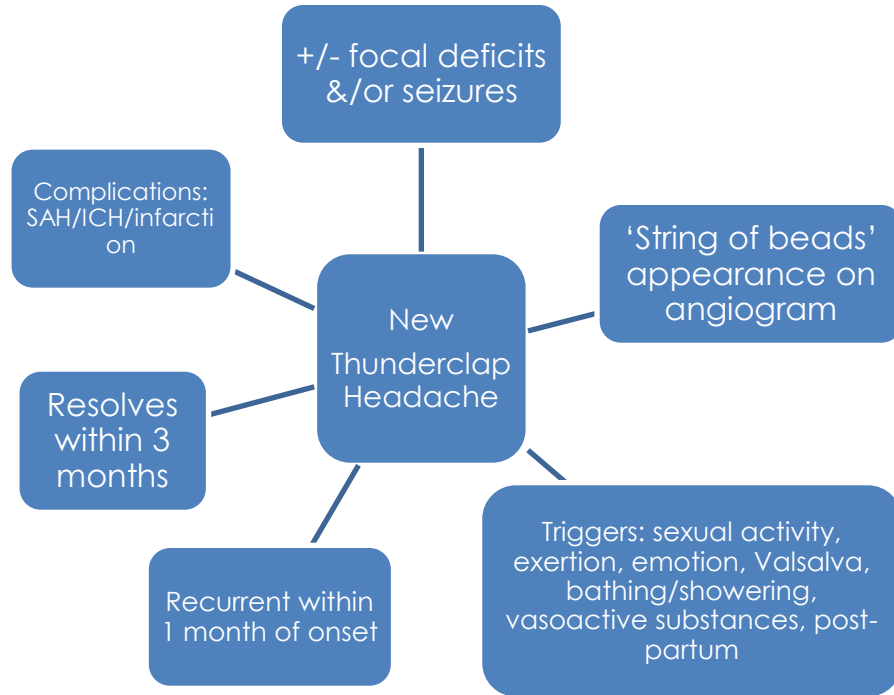
- A 45 year old woman presents with 2 THs. One occurred when in the shower and a further when in the gym doing weights. Both within a week of each other. They lasted around an hour.
- CT head was performed after 10 hrs of the 2nd attack and was normal.



What investigations would you do?

① Start presenting to display the poll results on this slide.

Reversible Vasoconstrictive Syndrome (RCVS)



Probable:

- Recurrent, severe TH, lasting >5 mins in 1 month
- Typical trigger
- Angiography is normal.

Nimodipine 30-60mg 4hrly



Case 3

- 54 year old lady with 3 episodes over a 3 week period of headaches reaching peak severity (9/10) within 1 minute of having an orgasm.
- No drug use or head trauma.
- Headaches last an hour and then remit.



What could be the diagnosis?

① Start presenting to display the poll results on this slide.

Primary Sexual Headache

- Overlap with RCVS
- 2 types:
 1. Progressive intensity with sexual activity
 2. TH with or just before orgasm
- **Brought on ONLY by sexual activity**
- Lasts from 60s -24hrs if severe, or 72 hrs if milder.
- More males compared to RCVS
- 35-45 yrs onset typically.
- Can occur with masturbation also.
- Migrainous features but NO autonomic/reduced consciousness



Other benign headaches

Primary Thunderclap Headache

- TH lasting >5 mins with no better diagnosis (secondary R/O)

Primary Cough Headache

- At least 2 TH **brought on by** coughing/straining or other Valsalva
- 1 sec to 2 hrs duration

Primary Exercise Headache

- At least 2 headaches (not just TH) brought on by physical exertion
- Lasts less than 48hrs

New Daily Persistent Headache

- Sudden or TH presentation, continuous/daily tension/migrainous since onset
- Lasting >3 months

Case 4

- 26 yr old male with occipital headache for past 3 weeks. Came on suddenly and daily since.
- Seen GP twice. Analgesia not helping. Feels nauseous. No light/sound sensitivity. Neck pain. 8/10 mobilising and 2/10 lying down.
- No history of trauma or drug use.



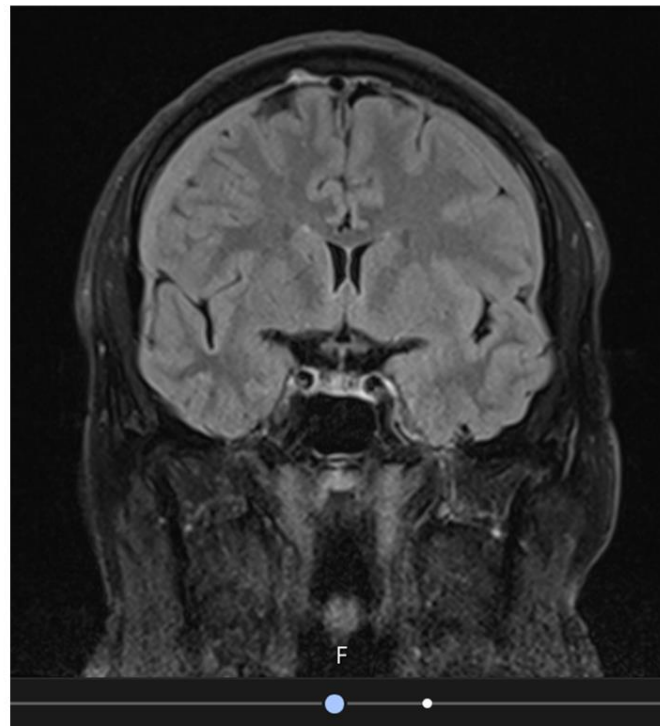
What could be the diagnosis?

① Start presenting to display the poll results on this slide.



Spontaneous IC Hypotension (SIH)

- MRI brain with contrast and Spine with STIR sequences
 - Can be normal
- Initial conservative management: lying flat + analgesia + fluids for 2 weeks
- ?Caffeine
- If failed, non-targeted blood patch.



Case 5

- A 31 year old female with a migraine history attends to ED after coughing and feeling a sudden pain in her head that was severe (10/10). Her headache has continued for the past 8 hrs.
- She complains of non-specific visual blurring and has vomited once.
- She has some mild weakness in her left arm and there is possible optic disc swelling.
- CT head was reported showing a bleed

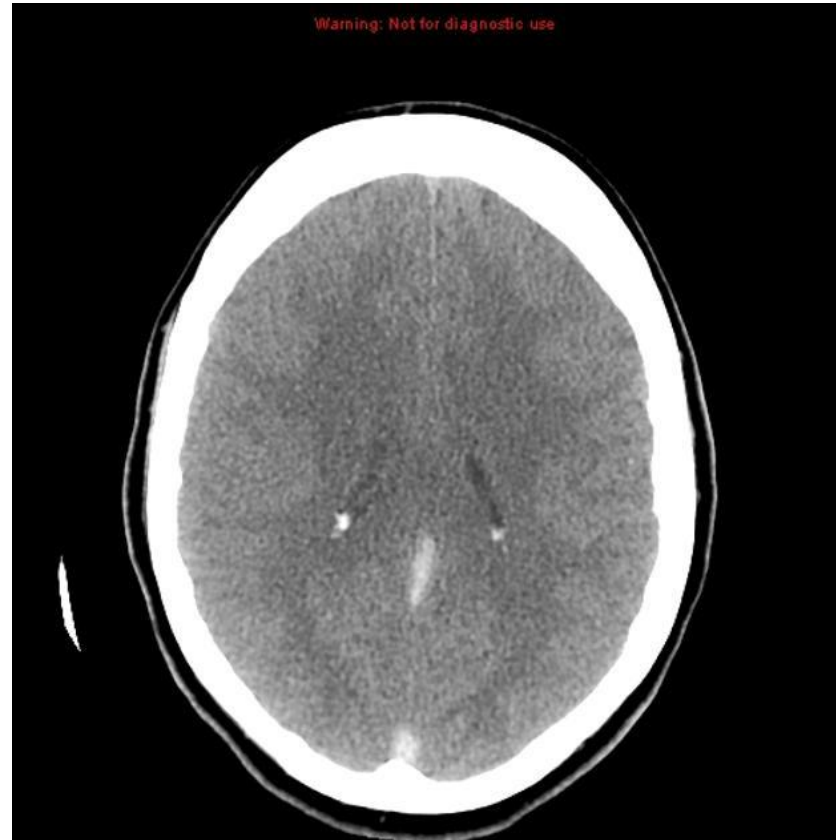


Image from Radiopaedia



What could be the diagnosis?

① Start presenting to display the poll results on this slide.



Conclusions

- Is this really a TH?
- If so, all new ones need extensive investigation.
- Not all TH are SAH, but many are.
- Consider RCVS, especially if recurrent.
- We should still do LPs for TH, for the moment.....



Thanks for listening